

# Management of *Toxoplasma gondii* Infection during Pregnancy

Jose G. Montoya and Jack S. Remington

Palo Alto Medical Foundation Toxoplasma Serology Laboratory, Palo Alto, and Department of Medicine and Division of Infectious Diseases and Geographic Medicine, Stanford University School of Medicine, Stanford, California

Acute infection with *Toxoplasma gondii* during pregnancy and its potentially tragic outcome for the fetus and newborn continue to occur in the United States, as well as worldwide, despite the fact that it can be prevented. The infection can be acquired through ingestion of infected, undercooked meat or contaminated food or water. Transmission to the fetus occurs almost solely in women who acquire their primary infection during gestation and can result in visual and hearing loss, mental and psychomotor retardation, seizures, hematological abnormalities, hepatosplenomegaly, or death. Systematic education and serological screening of pregnant women are the most reliable and currently available strategies for the prevention, diagnosis, and early treatment of the infection in the offspring; this is largely because toxoplasmosis in pregnant women most often goes unrecognized. Treatment of the infection in the fetus and infant during the first year of life has been demonstrated to significantly improve the clinical outcome.

*Toxoplasma gondii* infection acquired by pregnant women during gestation and its transmission to the fetus continue to be the cause of tragic yet preventable disease in the offspring [1]. In addition to the unfortunate outcome for infants and children are the emotional and economic burdens faced by the parents and society. It has been estimated that 500–5000 infants each year are born with congenital toxoplasmosis in the United States [2]. Although the majority of infants appear to be healthy at birth, significant long-term sequelae may become obvious only months or years later.

*T. gondii* infection is acquired primarily through ingestion of cysts in infected, undercooked meat or oocysts that may contaminate soil, water, and food. Meat (primarily pork and lamb) is an important source of the infection in humans in the United States [3]. However, the frequency at which the source is meat versus ingestion of oocysts among different populations and geographical areas in the United States is unknown. Recent studies have identified water as a potential source of the infection in both humans and animals [4–8].

The purpose of this review is to provide an update on the

diagnosis and management of toxoplasmosis during pregnancy in the United States. A more comprehensive review of the subject can be found elsewhere [1].

## CLINICAL MANIFESTATIONS DURING PREGNANCY

Transmission to the fetus occurs predominantly in women who acquire their primary infection during gestation. In rare cases, congenital transmission has occurred in chronically infected women whose infection was reactivated because of their immunocompromised state (e.g., from AIDS or treatment with corticosteroids for their underlying disease).

Most pregnant women with acute acquired infection do not experience obvious symptoms or signs [1, 9]. A minority may experience malaise, low-grade fever, and lymphadenopathy. Rarely, pregnant women will present with visual changes due to toxoplasmic chorioretinitis [10] as a result of recently acquired infection or reactivation of a chronic infection. A recent study revealed that 52% of mothers who gave birth to congenitally infected offspring could not recall experiencing an infection-related illness during pregnancy or an identifiable epidemiological risk factor [9]. In severely immunocompromised, chronically infected pregnant women (e.g., patients with AIDS and those receiving high-dose immunosuppressive therapy, including organ transplant recipients, patients with malignancies, and patients with connective tissue disorders), reactivation of

Received 15 January 2008; accepted 16 March 2008; electronically published 11 July 2008.  
Reprints or correspondence: Dr. Jose G. Montoya, Research Institute, Palo Alto Medical Foundation, Ames Bldg., 795 El Camino Real, Palo Alto, CA 94301 (gilberto@stanford.edu).

**Clinical Infectious Diseases** 2008;47:554–66

© 2008 by the Infectious Diseases Society of America. All rights reserved.  
1058-4838/2008/4704-0019\$15.00

DOI: 10.1086/590149

latent *T. gondii* infection resulted in congenital transmission of the parasite to the fetus [11–13].

### SPECIAL CONSIDERATIONS IN THE FETUS AND NEWBORN RELATED TO MATERNAL INFECTION

The frequency of vertical transmission increases with the gestational age (table 1) [1, 14]. In contrast, severe clinical signs in the infected infant are more commonly observed in offspring of women whose infection was acquired early in gestation (table 1).

Occasionally, the diagnosis of the infection in a pregnant woman is first considered when ultrasonographic findings reveal the presence of fetal abnormalities [1]. In other cases, it is first considered in a mother whose newborn has clinical manifestations of the infection.

### DIAGNOSIS DURING PREGNANCY

Serological tests and PCR are used in an attempt to diagnose toxoplasmosis in pregnant women (table 2) [1]. Transmission of the parasite to the fetus frequently occurs in pregnant women who have no history of illness during gestation or exposure to undercooked meat or to cats [9]. Therefore, the decision to perform *T. gondii* serological tests during pregnancy should not be based solely on clinical (e.g., presence or absence of symptoms) or epidemiological (i.e., history of exposure to *T. gondii*) grounds [1, 9].

Systematic serological screening for *T. gondii* IgG and IgM antibodies in all pregnant women as early in gestation as feasible (ideally during the first trimester) and in seronegative women each month or trimester thereafter would be optimal. Such screening allows for detection of seroconversion and early initiation of treatment. Although screening is rarely performed in the United States, such screening is mandated by law in some countries (e.g., France and Austria), to facilitate early detection

of recently acquired infection. Although we support the use of systematic serological screening during pregnancy, we acknowledge that factors such as cost, demographic characteristics, availability of appropriate tests, and the relatively low incidence of acute infection must be taken into consideration. An additional consideration is the recent controversy about the effectiveness of treatment during gestation in an attempt to prevent transmission to the fetus.

**Serological tests.** The detection (and quantification) of *T. gondii* antibodies in serum is used to establish whether a pregnant woman has been infected and, if so, to determine whether the infection was acquired recently or in the distant past. If serological test results suggest a recently acquired infection, an effort is made to determine whether the infection was likely acquired during gestation or shortly before conception. If so, the fetus is at risk.

In the United States, physicians most often submit only a single serum sample for serological testing, and from the results for that specimen, they expect a diagnosis. Thus, seroconversion is rarely demonstrable in the United States. Only approximately one-third of the samples submitted to our serology laboratory are obtained from women in their first trimester [1]. Serological test results of serum samples obtained later in gestation are frequently difficult to interpret. The earlier the serum sample is obtained, the more likely the results will prove clinically helpful. Testing of a serum sample drawn after the second trimester most often will not be able to exclude that an infection was acquired earlier in the pregnancy.

For serological diagnosis, IgG, IgM, IgA, and IgE antibodies; IgG avidity; and the differential agglutination (AC/HS) tests have been employed successfully in an attempt to distinguish the acute versus the chronic stage of the infection [15]. Except for measurement of IgG and IgM antibodies, most of these tests are performed only in reference laboratories (e.g., in the United States, at the Palo Alto Medical Foundation Toxoplasma

**Table 1. Risk of *Toxoplasma gondii* congenital infection (transmission) and development of clinical signs in offspring before age 3 years, according to gestational age at maternal seroconversion.**

Gestational age at maternal seroconversion, weeks	Risk of congenital infection (95% CI), %	Development of clinical signs in the infected offspring (95% CI), %	Risk of development of clinical signs when infection status is unknown, <sup>a</sup> %
13	6 (3–9)	61 (34–85)	4
26	40 (33–47)	25 (18–33)	10
36	72 (60–81)	9 (4–17)	7

**NOTE.** This analysis was performed with 603 women whose *T. gondii* infection was documented to have occurred during gestation. Anti-*Toxoplasma* treatment was administered to 504 (84%) of the women. Data are from [14].

<sup>a</sup> Risk of development of clinical signs of infection in a child whose mother was known to have been infected during gestation but in whom congenital infection has not been established yet (values are obtained by multiplying the risk of congenital infection by the risk of signs among congenitally infected children).

**Table 2. Laboratory tests available for diagnosis of toxoplasmosis during pregnancy and the distinguishing features between serological testing at nonreference laboratories and at Palo Alto Medical Foundation Toxoplasma Serology Laboratory (PAMF-TSL).**

Diagnostic tests	Use	Available tests	Storage of serum samples	Assistance to clinicians
<b>Serological tests</b>				
At nonreference or commercial laboratory	Useful for initial screening because only ~10% of pregnant women in the US are seropositive	IgG: positive or negative results are usually reliable; IgM: negative results are most often reliable, and positive or equivocal results require confirmatory testing at reference laboratory	Samples are usually discarded after testing and are not available for future parallel testing	Usually not available
At reference laboratory (PAMF-TSL <sup>a</sup> )	Particularly useful for pregnant women with positive or equivocal IgM test results	IgG (dye test), IgM, IgA, IgE, AC/HS, avidity, agglutination	Samples are stored for $\geq 1$ year for potential future parallel testing	Provided by physician consultants
<b>Amniotic fluid PCR</b>	Should be performed at 18 weeks of gestation or as soon as feasible thereafter for pregnant women with suspected or proven toxoplasmosis during pregnancy; 35-multi-copy B1 gene is commonly used as the target	...	...	...
<b>Ultrasound</b>	Should be performed (ideally every month) for pregnant women with suspected or proven <i>T. gondii</i> infection acquired during pregnancy	...	...	...

<sup>a</sup> <http://www.pamf.org/serology/>; telephone number (650) 853-4828; e-mail, [toxolab@pamf.org](mailto:toxolab@pamf.org).

Serology Laboratory [PAMF-TSL]; Palo Alto, CA; <http://www.pamf.org/serology/>; telephone number (650) 853-4828; e-mail, [toxolab@pamf.org](mailto:toxolab@pamf.org)). Currently, the IgG avidity test is not commercially available in the United States. Ongoing studies at PAMF-TSL are in progress with the VIDAS IgG avidity kit (bioMérieux), which is widely used in western Europe. An avidity test is also available at FOCUS Laboratories (Cypress, CA).

Serological testing for both IgG and IgM antibodies at clinical, nonreference laboratories should be performed initially. In the vast majority of cases, testing early in gestation can establish either that infection has not occurred, by the absence of both IgG and IgM antibodies, or that infection was acquired in the distant past, by positive IgG and negative IgM antibody test results (table 3). Additional assistance with confirmatory testing in reference laboratories is required primarily for patients with positive or equivocal IgM antibody test results. A reference laboratory such as PAMF-TSL often can determine whether a patient with a positive IgM antibody test result acquired the infection recently or in the distant past.

Physicians and laboratory personnel should realize the significant and often unfortunate delays that may occur between the date that the serological tests are ordered and the date that the results are actually reported back to the health care provider and the patient. This is particularly the case when results obtained at nonreference laboratories require confirmatory testing at a reference laboratory.

Appropriate interpretation of serological test results can best be achieved when adequate clinical information (i.e., gestational age, reason for testing, and presence of abnormal clinical or laboratory findings in the mother or the fetus) is made available to experienced consultants. Too frequently, serological tests are requested, but information about the patient is not provided. Lack of clinical information often results in suboptimal inter-

pretation of results and limits the ability to provide appropriate recommendations.

It needs to be emphasized that a positive IgM antibody test result at any time before or during gestation does not necessarily mean a recently acquired infection [16–18]. IgM antibodies may persist for 1 year following acute infection, and most positive IgM antibody test results are obtained in pregnant women who acquired their infection in the more distant past and beyond the period of fetal risk. These patients are chronically infected. Recently, we examined 100 consecutive serum samples submitted to PAMF-TSL because of a positive IgM antibody test result at an outside clinical laboratory. Confirmatory testing at PAMF-TSL revealed that 62% of these serum samples were negative for IgM antibody. This percentage is essentially the same as that we reported 7 years ago [19]. Additional testing confirmed that infection in such cases was acquired in the more distant past rather than recently. The greatest value of a positive IgM antibody test result is that it raises the question of a recently acquired infection, thereby necessitating confirmatory testing in a reference laboratory.

Figure 1 shows interpretation of results of serological tests performed at clinical laboratories. Serological testing for both IgG and IgM antibodies at clinical (nonreference) laboratories should be performed initially. Negative results of *Toxoplasma* IgG and IgM antibody tests, as well as positive results of IgG tests, tend to be accurate. Initial screening and testing for toxoplasmosis can be accomplished by these laboratories (table 3).

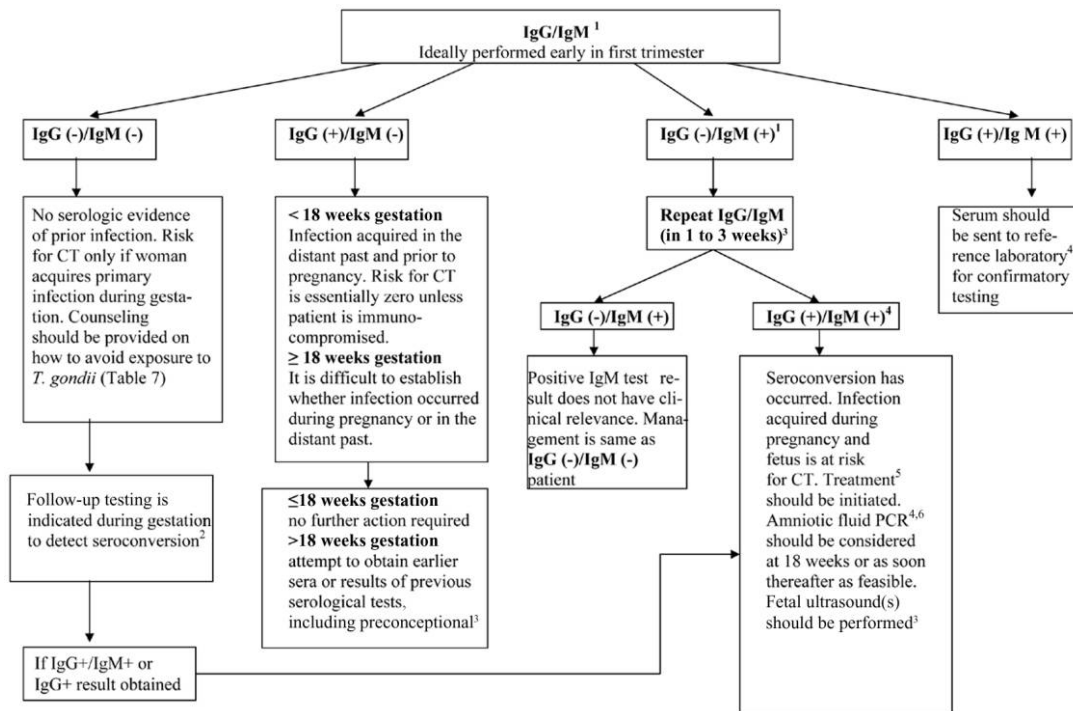
Figure 2 shows the procedure for confirmatory testing of positive IgM test results at a reference laboratory. A battery of serological tests is usually required in an attempt to establish whether a positive or equivocal IgM test result is clinically relevant (i.e., whether it is indicative of an infection acquired during gestation) [17]. It is noteworthy that only ~40% of positive IgM test results obtained at nonreference laboratories

**Table 3. Interpretation of results of serological tests for toxoplasmosis performed at clinical (nonreference) laboratories.**

IgG test result	IgM test result	Clinical relevance
Negative	Negative	Interpreted to indicate that the woman has not been infected with <i>Toxoplasma gondii</i> . Serial testing during pregnancy is advised. If such women acquire primary infection during gestation, they are at risk of transmitting the infection to their fetus.
Positive	Negative	During the first or second trimester, most often reflects an infection acquired before the present pregnancy <sup>a</sup>
Negative	Positive or equivocal	IgM antibodies are detected early in the acute infection. Because they may persist for prolonged periods, IgM antibodies may be detected in pregnant women who were infected in the distant past and before gestation. Therefore, a positive (or equivocal) IgM test result should be followed by confirmatory testing at a <i>Toxoplasma</i> reference laboratory <sup>b</sup> [17]
Positive	Positive or equivocal	Same as above

<sup>a</sup> In the third trimester, this result is more difficult to interpret. Although it is most consistent with an infection acquired before pregnancy, in some patients, this result may reflect an infection that was acquired early in gestation and that was accompanied by an increase in the IgM titer and a decrease to nondetectable levels within a relatively brief period of time.

<sup>b</sup> For example, the Palo Alto Medical Foundation Toxoplasma Serology Laboratory, telephone number (650) 853-4828; e-mail, [toxolab@pamf.org](mailto:toxolab@pamf.org).



**Figure 1.** Guidelines for serological testing and management of toxoplasmosis during pregnancy on the basis of initial results obtained from *Toxoplasma gondii* IgG and IgM antibody tests performed at clinical (nonreference) laboratories. <sup>1</sup>Initial serological screening with IgG and IgM tests usually can be reliably performed at nonreference laboratories. Certain laboratories or clinicians may choose to send serum samples at this initial stage directly to a reference laboratory; interpretation of results obtained in a reference laboratory usually will be the same as that shown here for nonreference laboratories. <sup>2</sup>The interval for serological screening varies by the center and country where systematic serological screening is performed (e.g., every month in France). Systematic serological screening to detect early infection acquired during gestation is not performed in the United States. <sup>3</sup>Consider consultation with a physician expert in management of toxoplasmosis during pregnancy (e.g., at Palo Alto Medical Foundation Toxoplasma Serology Laboratory [PAMF-TSL], telephone number (650) 853-4828, or US [Chicago, IL] National Collaborative Treatment Trial Study, telephone number (773) 834-4152). <sup>4</sup>Consider sending samples to a reference laboratory such as PAMF-TSL [17]. <sup>5</sup>Treatment with spiramycin or with pyrimethamine, sulfadiazine, and folinic acid (see text and table 6). <sup>6</sup>Amniotic fluid PCR should be performed at 18 weeks of gestation (not before) or later. In patients at >18 weeks of gestation, the risk of the procedure should be carefully weighed against the potential benefit of diagnosing fetal infection (see text and tables 2 and 5). CT, congenital toxoplasmosis.

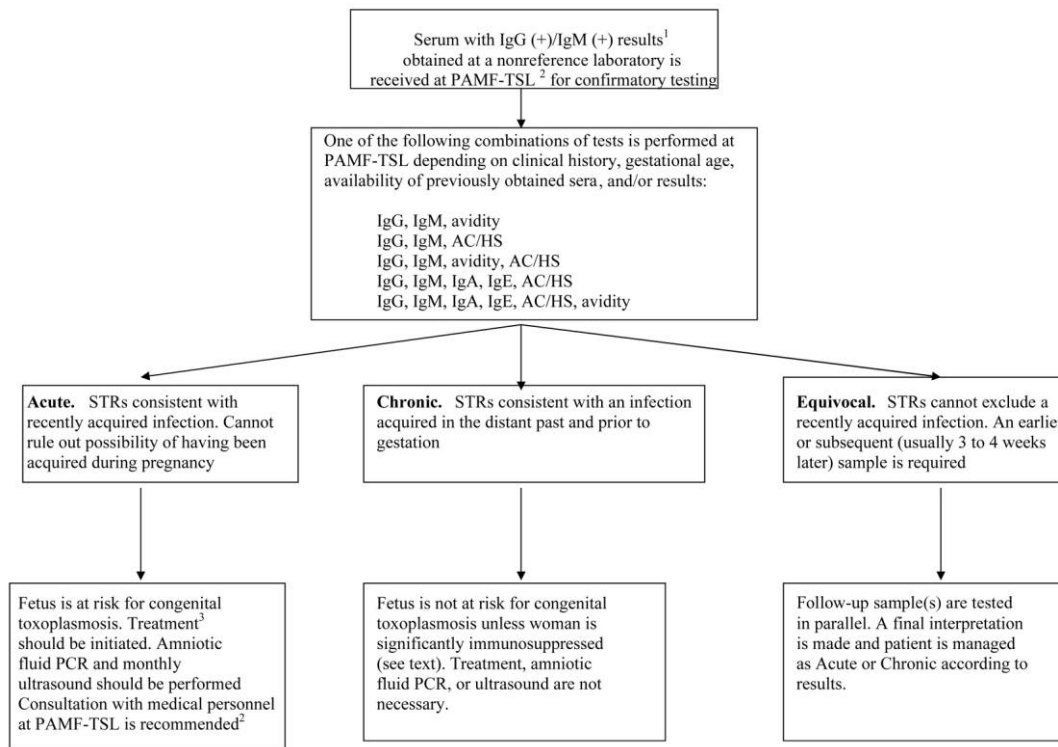
in the United States were found for patients who had acquired their primary (acute) infection in the recent past [19].

Confirmatory testing of a positive IgM test result by the use of additional tests in various combinations has been validated by reference laboratories in Europe and the United States (tables 2 and 4) [15, 20, 21]. An example is the battery of tests (*Toxoplasma* serological profile [TSP]) used at PAMF-TSL. The TSP comprises the dye test (which measures primarily IgG antibodies); IgM, IgA, and IgE ELISAs; and the AC/HS test [1]. The methods used for demonstration of IgM, IgA, and IgE antibodies at the PAMF-TSL were developed by that laboratory and are not available elsewhere. In addition to the reporting of serological test results, consultants at PAMF-TSL offer medical interpretation of results and are available to assist clinicians in management of their patients' conditions.

The TSP has been used successfully at PAMF-TSL in attempts to determine whether a pregnant woman acquired her infection during or before gestation. This distinction is important with

regard to decisions about prenatal drug intervention(s) and additional diagnostic tests, such as PCR and ultrasound. In addition, correct interpretation of the TSP results and their communication to the patient's physician by an expert were reported to decrease the rate of unnecessary abortions by ~50% among women in the United States for whom positive IgM test results had been reported by outside laboratories [19].

A *Toxoplasma* IgG avidity test has also been used at PAMF-TSL since July 2000. It is used only in conjunction with the AC/HS test and, when indicated, with other tests in the TSP [22, 23]. High-avidity IgG antibodies develop at least 12–16 weeks (depending on the test method used) after infection. The presence of high-avidity antibodies in the TSP indicates that infection was acquired >16 weeks earlier [22, 24, 25]. Thus, in a pregnant woman in the first months of gestation, regardless of the IgM antibody test result, a high-avidity IgG test result indicates that the fetus is essentially not at risk for congenital toxoplasmosis. A high-avidity IgG test result is especially useful



**Figure 2.** Serological testing and management of toxoplasmosis during pregnancy on the basis of results obtained at the Palo Alto Medical Foundation Toxoplasma Serology Laboratory (PAMF-TSL), telephone number (650) 853-4828. <sup>1</sup>A serum sample with positive results of IgG and IgM antibody tests is the most common reason for requesting confirmatory testing at PAMF-TSL. <sup>2</sup>PAMF-TSL or US (Chicago, IL) National Collaborative Treatment Trial Study, telephone number (773) 834-4152. <sup>3</sup>Treatment with spiramycin or with pyrimethamine, sulfadiazine, and folinic acid (see text and table 6). AC/HS, differential agglutination test; STRs, serological test results at PAMF-TSL; TSP, *Toxoplasma* serological panel.

when only a single sample of serum has been obtained in which *T. gondii* IgM antibodies are present and for which the AC/HS test (or the TSP) reveals an acute or equivocal pattern. For pregnant women beyond 16 weeks of gestation, a high-avidity test result may be helpful in establishing that the infection was acquired at least 12–16 weeks earlier in gestation; in this scenario, the transmission rate would be lower [14], the potential for fetal damage would be greater (table 1) [14], and the negative predictive value of the amniotic fluid PCR would be greater (table 5) [26] than if the infection was acquired later in gestation. Of special note is that low-avidity or equivocal test results can persist for many months or a year or more after the primary infection and, for this reason, must not be used alone to determine whether the infection was recently acquired [22, 27]. In fact, in serum samples with low- or borderline-avidity antibodies and negative IgM antibody test results or a TSP reflecting an infection acquired in the distant past, the IgG avidity test is not useful and, if used alone, can potentially be misleading [28].

Confirmatory testing with the TSP and the avidity method during the first 16 weeks of gestation has the potential to decrease the need for follow-up serum samples and thereby reduce costs, to make the need for PCR of amniotic fluid and for

treatment with spiramycin for the mother unnecessary, to remove the pregnant woman's anxiety associated with further testing, and to decrease unnecessary abortions. Final interpretation of results of serological tests performed at PAMF-TSL yields 3 possibilities: (1) results are consistent with a recently acquired infection, and thus the possibility that the patient acquired her infection during gestation or shortly before conception cannot be excluded; (2) results are consistent with an infection acquired in the distant past and before pregnancy; or (3) results are equivocal, which usually requires a follow-up serum sample for parallel testing (figure 2 and table 4).

**PCR.** Amplification of *T. gondii* DNA in amniotic fluid at 18 weeks of gestation (the optimal time) or later has been used successfully for prenatal diagnosis of congenital toxoplasmosis [26, 29, 30]. Its sensitivity and specificity for amniotic fluid obtained before 18 weeks of gestation have not been studied; in addition, the procedure done early in gestation is associated with a higher risk to the fetus and likely is less useful. A definitive study of the routine use of PCR of amniotic fluid obtained at 18 weeks of gestation or later was reported in France to have an overall sensitivity of 64% for the diagnosis of congenital infection in the fetus, a negative predictive value of 88%, and a specificity and positive predictive value of 100% (i.e., a

**Table 4. Examples of final interpretation of results of confirmatory tests performed at Palo Alto Medical Foundation Toxoplasma Serology Laboratory (PAMF-TSL) on serum samples that had positive results of IgM antibody tests at clinical laboratories.**

Patient (weeks of gestation)	Clinical (nonreference) laboratory results of IgG/IgM tests	PAMF-TSL results for test						Interpretation
		IgG (dye test), IU/mL	IgM	IgA	IgE	AC/HS <sup>a</sup> pattern	Avidity	
A (11)	+/+	8000	+	+	+	Acute	Low	Consistent with recently acquired infection
B (9)	+/+	256	+	-	-	Equivocal	High	Consistent with infection acquired in the distant past (i.e., 6 months ago)
C (12)	+/+	4096	-	-	-	Nonacute	Low	Consistent with infection acquired in the distant past
D (12)	+/equivocal	1024	+	+	-	Equivocal	Low	Cannot exclude recently acquired infection; test of earlier or subsequent sample is required for further clarification

<sup>a</sup> Differential agglutination.

positive result signifies infection of the fetus) (table 5) [26]. Gestational age had a significant influence on the sensitivity and negative predictive values [26]. Sensitivity was statistically significantly higher when maternal infection occurred at 17–21 weeks of gestation, compared with when infection occurred before 17 weeks or after 21 weeks of gestation ( $P < .02$ ) [26]. However, the negative predictive value of PCR of amniotic fluid from women who acquired the infection early in gestation (e.g., before week 7 of gestation) was ~100% because of the very low transmission rate during that time in gestation [26]. Romand et al. [31] also demonstrated that the parasite load in amniotic fluid is an independent risk factor for severity of fetal infection, in addition to the gestational age. Maternal infections acquired before 20 weeks of gestation with a parasite load >100 parasites per mL of amniotic fluid was associated with the

highest risk of severe outcome in the fetus. In clinical practice, amniocentesis has essentially replaced fetal blood sampling for diagnosis of congenital toxoplasmosis, because of its inherently lower risk and higher sensitivity [1, 30].

PCR techniques for detection of *T. gondii* DNA in amniotic fluid or other samples are not standardized, and there is no consensus on the best protocol to use [26, 29, 31–34]. The specimen should be sent to a laboratory experienced in performing this assay on amniotic fluid and that has proper validation and quality-control data and experience in interpretation of its results.

Amniotic fluid examination by PCR should be considered for pregnant women (without a contraindication for the procedure) who (1) have serological test results diagnostic or highly suggestive of an infection acquired during gestation or shortly before conception; (2) have evidence of fetal damage by ultrasonographic examination (e.g., ventriculomegaly or hepatic or brain calcifications); or (3) are significantly immunosuppressed and thus at risk of reactivation of their latent infection (with the exception of women with AIDS). Amniocentesis may be less advisable for patients coinfecting with *T. gondii* and HIV, because of the risk of infecting the fetus with HIV during the amniocentesis. PCR also may be useful for demonstration of parasite DNA in fetal tissues and placenta [35].

**Ultrasound.** Ultrasound is recommended for women with suspected or diagnosed acute infection acquired during or shortly before gestation. Ultrasound may reveal the presence of fetal abnormalities, including hydrocephalus, brain or hepatic calcifications, splenomegaly, and ascites [1].

The clinical outcome of congenitally infected children whose mothers had acquired the infection during the first trimester of pregnancy, whose fetal ultrasound findings were normal, and who received spiramycin during gestation was recently reported. Although these children were expected to have severe damage (table 1), their 2-year follow-up revealed that their outcomes did not differ significantly from those of infected

**Table 5. Rates of congenital transmission in 270 women and the sensitivity and negative predictive value (NPV) of amniotic fluid PCR for prenatal diagnosis of congenital toxoplasmosis, according to gestational age at which maternal infection was acquired.**

Gestational age at maternal infection, <sup>a</sup> weeks	No. of infected fetuses/total no. of fetuses (%)	Amniotic fluid PCR	
		Sensitivity, %	NPV, %
≤6	0/14 (0)	NA	100
7–11	7/50 (14)	28.6	89.6
12–16	7/61 (11)	57.1	94.7
17–21	14/66 (21)	92.9	98.1
22–26	16/36 (44)	62.5	76.9
27–31	19/30 (63)	68.4	64.7
32	12/13 (92)	50	14.3
Total	75/270 (28)	NA	NA

**NOTE.** The positive predictive value was 100%, regardless of gestational age. Data are from [26]. NA, not applicable.

<sup>a</sup> Maternal infection was diagnosed by seroconversion in the 270 women; 261 (97%) were given treatment with spiramycin.

<sup>b</sup> Congenital infection was diagnosed by the persistence of *Toxoplasma* IgG antibodies after 1 year of life.

children born to mothers who had acquired the infection during the second and third trimesters (table 1) [36]. The authors concluded that, in such circumstances, termination of pregnancy was not indicated. However, appropriate treatment was essential, and prenatal ultrasound findings should be free of any anomaly [36]. In addition to ultrasound, CT has been used to search for brain calcifications, and MRI for other abnormalities in the fetus.

***Histological analysis and attempts to isolate the parasite.***

Occasionally, placental or fetal tissues from pregnant women suspected of having acquired acute infection during gestation are available to attempt to determine whether vertical transmission of the parasite has occurred. *T. gondii* cysts may be visualized in these tissues with the Wright-Giemsa stain, but immunoperoxidase staining using *T. gondii*-specific antibodies is more sensitive [37]. Isolation of the parasite can be attempted by inoculation of tissues into tissue culture or mice [1].

**APPROACH FOR PATIENTS WITH SUSPECTED OR DIAGNOSED *T. GONDII* INFECTION ACQUIRED DURING GESTATION**

Once it has been established that serological test results are consistent with a recently acquired infection and that acquisition of the infection during the first 18 weeks of gestation or shortly before conception cannot be excluded, an attempt to prevent vertical transmission of the parasite through treatment with spiramycin is recommended for the mother by many investigators in the United States and Europe (figure 3). If fetal infection is confirmed by a positive result of PCR of amniotic fluid at 18 weeks of gestation or later, treatment with pyrimethamine, sulfadiazine, and folinic acid is recommended (if the patient is already receiving spiramycin, the recommendation is to switch to this combination). In some centers in Europe, this switch takes place as early as week 14–16 [38].

Because of the high transmission rates observed after 18 weeks of gestation, treatment with pyrimethamine, sulfadiazine, and folinic acid is also used for patients who have acquired the infection after 18 weeks of gestation, in an attempt to prevent fetal infection from occurring and, if transmission has occurred, to provide treatment for the fetus (figure 3). Pyrimethamine is not used earlier because it is potentially teratogenic.

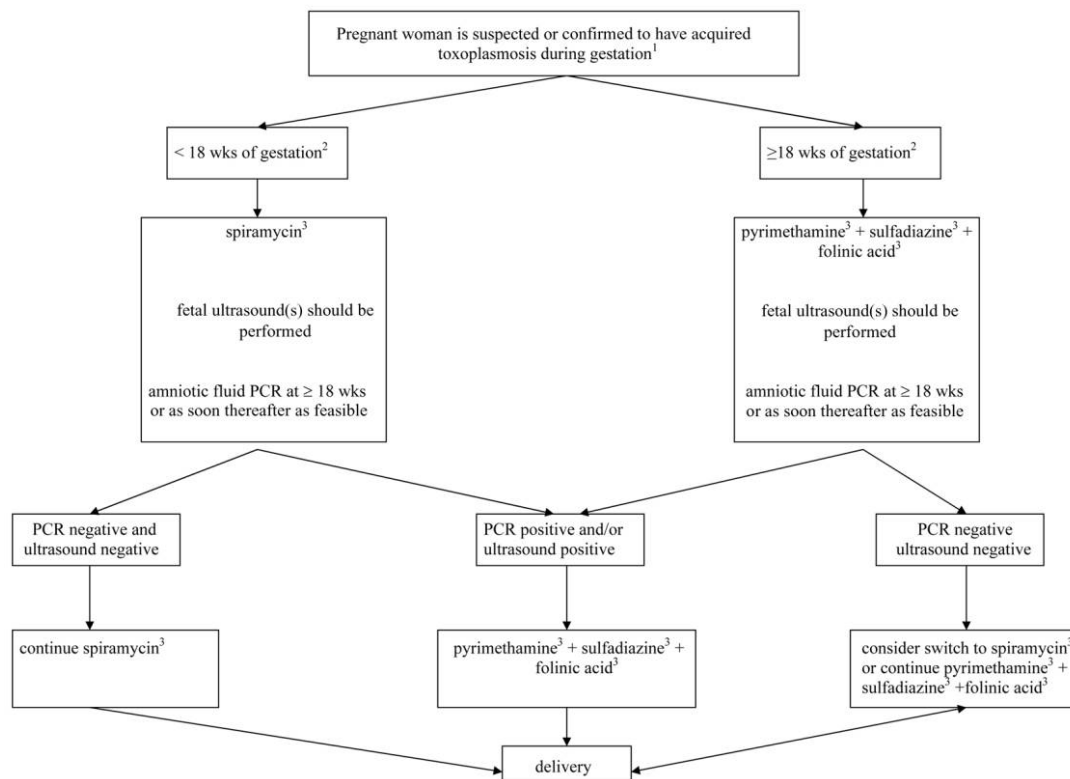
***Spiramycin.*** The use of the macrolide antibiotic spiramycin has been reported to decrease the frequency of vertical transmission [30, 39–42]. However, carefully designed, prospective studies that demonstrate this effect have not been performed. The protection has been reported to be more distinct in women infected during their first trimester [39, 40, 42]. In studies using historical controls, the incidence of congenital infection was reduced by ~60% [39, 40, 42]. Spiramycin does not readily cross the placenta and thus is not reliable for treatment of infection in the fetus. There is no evidence that spi-

ramycin is teratogenic (table 6). The drug is administered until delivery even in those patients with negative results of amniotic fluid PCR, because of the theoretical possibility that fetal infection can occur later in pregnancy from a placenta that was infected earlier in gestation [42]. For pregnant women in whom the possibility of fetal infection is high or fetal infection has been established, treatment with spiramycin should be switched after the 18th week of gestation to treatment with pyrimethamine, sulfadiazine, and folinic acid. In some centers, change to such treatment occurs earlier (e.g., at 14–16 weeks of gestation) [38].

Spiramycin is not commercially available in the United States. It can be obtained at no cost and after consultation (with PAMF-TSL, telephone number (650) 853-4828, or the US [Chicago, IL] National Collaborative Treatment Trial Study [NCCTS], telephone number (773) 834-4152) through the US Food and Drug Administration, telephone number (301) 796-1600. It is administered orally at a dosage of 1.0 g (or 3 million U) every 8 h (total dosage of 3 g or 9 million U per day). Through this program, Sanofi-Aventis, for many years, has kindly been providing spiramycin to pregnant women in the United States at no cost.

In recent years, the effectiveness of spiramycin to prevent congenital toxoplasmosis has become controversial [38, 43]. Members of the European Multicentre Study on Congenital Toxoplasmosis (EMSCOT) have raised the question as to the value of such treatment [38, 43]. These investigators have stated repeatedly that carefully designed studies are necessary to clarify whether spiramycin is efficacious in prevention of congenital toxoplasmosis. We agree with that specific statement. Recent data from the EMSCOT investigators suggest that spiramycin may be more efficacious when administered early after seroconversion [43]. The studies supporting both positions (for and against the recommendation of spiramycin treatment) primarily suffer from a lack of randomization and necessary controls in their design and from small sample sizes for the group of untreated women [30, 38–43]. The data provided to date have not ruled out a potential benefit from spiramycin [44]. It has been suggested, and we agree, that only a large, randomized, controlled clinical trial would provide clinicians and patients with valid evidence of the potential benefit of prenatal treatment with spiramycin [43]. Until there is further clarification on this subject, we continue to recommend spiramycin treatment for women with suspected or confirmed acute *T. gondii* infection acquired during the first 18 weeks of gestation [1].

***Pyrimethamine, sulfadiazine, and folinic acid.*** Until further information is available, we consider it justifiable to recommend the combination of pyrimethamine, sulfadiazine, and folinic acid as treatment for pregnant women who acquire the infection after 18 weeks of gestation and for those in whom



**Figure 3.** Approach for pregnant women who are suspected or confirmed to have toxoplasmosis acquired during gestation. <sup>1</sup>Consultation with a reference laboratory or physician expert in toxoplasmosis is suggested (i.e., Palo Alto Medical Foundation Toxoplasma Serology Laboratory, telephone number (650) 853-4828, or US [Chicago, IL] National Collaborative Treatment Trial Study, telephone number (773) 834-4152). <sup>2</sup>Gestational age at which maternal infection was suspected or confirmed to have been acquired (or the best estimate); this is not the gestational age at which the patient consulted with or was seen by the health care provider. <sup>3</sup>For dosages and comments, see table 6. Folic acid should not be used as a substitute for folinic acid. wks, Weeks.

fetal infection has been confirmed (i.e., by positive result of amniotic fluid PCR) or is highly suspected (e.g., because of fetal abnormalities consistent with congenital toxoplasmosis detected by ultrasound examination) (table 6) [1, 45]. This drug regimen is used in an attempt to treat the infection in the fetus and, in some instances, with the hope of preventing transmission, especially in those women for whom amniocentesis for PCR testing cannot be performed and whose infection was acquired after 18 weeks of gestation [46]. Pyrimethamine is potentially teratogenic and should not be used in the first trimester of pregnancy. The drug produces reversible, usually gradual, dose-related depression of the bone marrow. All patients who receive pyrimethamine should have complete blood cell counts frequently monitored. Folic acid (not folinic acid) is used for reduction and prevention of the hematological toxicities of the drug.

We suggest that each case involving a pregnant woman suspected of having or given the diagnosis of acute *T. gondii* infection acquired during gestation be discussed with an expert in the management of toxoplasmosis (in the United States, e.g., PAMF-TSL or NCCTS).

### APPROACH FOR OTHERWISE IMMUNOCOMPETENT PATIENTS WITH *T. GONDII* INFECTION MOST LIKELY ACQUIRED 6 MONTHS BEFORE GESTATION

Because the incidence of congenital toxoplasmosis in the offspring of women who are known to have been infected before gestation or whose serological test results reveal infection acquired in the distant past (before gestation) has been shown to be extremely low (approaching zero), use of treatment with spiramycin or with pyrimethamine, sulfadiazine, and folinic acid and prenatal diagnosis of fetal infection are not indicated unless the mother is immunocompromised.

### APPROACH FOR IMMUNOCOMPROMISED PATIENTS WITH *T. GONDII* INFECTION ACQUIRED BEFORE GESTATION

Women who are coinfecting with HIV and *T. gondii* and who have developed AIDS are at risk of reactivating their *T. gondii* infection, developing severe toxoplasmosis (i.e., toxoplasmic encephalitis, pneumonia, etc.), and/or transmitting the parasite

**Table 7. Measures to prevent primary *Toxoplasma gondii* infection during pregnancy.**

---

Prevention measures
Cook meat to "well done" or thoroughly to 67°C (153°F). Meat should not be "pink" in the center.
Note that meat that is smoked, cured in brine, or dried may still be infectious
Avoid mucous membrane contact when handling raw meat
Wash hands carefully after contact with raw meat
Kitchen surfaces and utensils that have come in contact with raw meat should be washed wearing gloves
Refrain from skinning or butchering animals
Avoid contact with materials potentially contaminated with cat feces, especially when handling cat litter or gardening. Wearing gloves is recommended when these activities cannot be avoided.
Disinfect emptied cat-litter box with near-boiling water for 5 min before refilling
Wash fruits and vegetables before consumption
Avoid drinking water potentially contaminated with oocysts

---

to their offspring [1, 11]. Fortunately, such transmission is surprisingly rare [1, 11]. At present, data are insufficient to define the effectiveness of treatment intended to prevent vertical transmission of *T. gondii* in an HIV-infected woman. Until more data become available, we suggest that *Toxoplasma*-seropositive pregnant women whose CD4 cell count is <200 cells/mm<sup>3</sup> receive trimethoprim-sulfamethoxazole (80 mg trimethoprim and 400 mg sulfamethoxazole in a single-strength tablet, 1 tablet per day; this treatment is commonly used to prevent *Pneumocystis* pneumonia in such patients) in an attempt to prevent both reactivation of their *Toxoplasma* infection and transmission of the parasite to their offspring. Trimethoprim is usually avoided in the first trimester, because it is a folic acid antagonist. For women whose CD4 cell count is >200 cells/mm<sup>3</sup> and for non-HIV infected, immunocompromised women, spiramycin treatment is suggested for the duration of the pregnancy. Unfortunately, there are no studies to determine whether these strategies are effective.

Performance of amniotic fluid PCR may not be advisable for HIV-infected women because of the risk of facilitating the transmission of HIV to the fetus during the procedure. Amniotic fluid PCR should be considered for non-HIV infected, immunocompromised pregnant women who are chronically infected with *T. gondii* (as well as those who acquire the infection during pregnancy). Monthly ultrasound examinations should be considered as well for all immunocompromised pregnant women chronically infected with *T. gondii*.

#### **APPROACH FOR PREGNANT WOMEN WITH TOXOPLASMIC CHORIORETINITIS**

Pregnant women given a diagnosis of toxoplasmic chorioretinitis should have serological evaluation to establish whether the infection was acquired recently or in the distant past. Pregnant women with toxoplasmic chorioretinitis as a result of reactivation of a latent infection (acquired before gestation) do not appear to have a higher risk for transmission of the parasite to their offspring than that of pregnant women who were in-

fectured before gestation and who do not have active ocular toxoplasmosis [10]. Those with toxoplasmic chorioretinitis, considered to be a manifestation of recently acquired infection [47], should be given treatment for the infection, for both the eye disease and the risk of transmission of the infection to their fetus. In this scenario, the reader is referred to the approach described above in the Approach for Patients with Suspected or Diagnosed *T. gondii* Infection Acquired during Gestation section.

#### **APPROACH FOR PATIENTS WITH RECENTLY ACQUIRED *T. GONDII* INFECTION WHO WANT TO KNOW WHEN IT IS SAFE TO BECOME PREGNANT**

After a nonpregnant woman of childbearing age receives a diagnosis of a recently acquired *T. gondii* infection, the question frequently arises as to when they can safely become pregnant, with regard to the risk of congenital transmission of the parasite. It should be understood that there are no definitive data on this subject. Our advice has been conservative; we recommend that such women wait 6 months (from the date that the acute infection was diagnosed or documented) before attempting to become pregnant. Each case should be considered separately and, preferably, in consultation with an expert.

#### **PREVENTION**

**Primary prevention.** Educational materials that contain messages on how to prevent pregnant women from becoming infected have resulted in reduced rates of seroconversion (table 7) [48–50]. Educational measures should be in written form (e.g., books, magazines, or simple handouts), available in different languages, and integrated into existing prenatal programs, visits, and classes. Ultimately, it is the responsibility of health care policy makers and physicians to educate both pregnant women and women who are considering becoming pregnant, with regard to preventive measures. The need to take

**Table 6. Medicines used for pregnant women who have suspected or confirmed *Toxoplasma gondii* infection acquired during gestation.**

Treatment	Dosage	Comments
Spiramycin	1 g (3 million U) every 8 h (for a total of 3 g or 9 million U per day)	Not teratogenic; does not treat infection in the fetus; indicated for pregnant women suspected of having acquired the infection at <18 weeks of gestation. Spiramycin treatment should be continued until delivery in women with low suspicion of fetal infection or those with documented negative results of amniotic fluid PCR and negative findings on ultrasounds at follow-up. Available in the United States only through the Investigational New Drug process at the FDA. Prior consultation with medical consultants <sup>a</sup> is required.
Pyrimethamine, sulfadiazine, and folic acid	Pyrimethamine: 50 mg every 12 h for 2 days followed by 50 mg daily; sulfadiazine: initial dose of 75 mg/kg, followed by 50 mg/kg every 12 h (maximum, 4 g/day); folic acid <sup>b</sup> (leucovorin): 10–20 mg daily (during and 1 week after completion of pyrimethamine therapy)	Pyrimethamine is teratogenic; therefore, this combination should not be used before week 18 of gestation (in some centers in Europe, it is used as early as week 14–16). Indicated for women suspected of having acquired infection at 18 weeks of gestation and those with documented fetal infection (positive result of amniotic fluid PCR) or abnormal ultrasound findings suggestive of congenital toxoplasmosis, given when patient is at 18 weeks of gestation

**NOTE.** FDA, US Food and Drug Administration.

<sup>a</sup> Palo Alto Medical Foundation Toxoplasma Serology Laboratory, telephone number (650) 853-4828, or US (Chicago, IL) National Collaborative Treatment Trial Study, telephone number (773) 834-4152.

<sup>b</sup> Folic acid should not be used as a substitute for folic acid.

these preventive measures continually must be reinforced throughout pregnancy for seronegative women. [48, 51]. Table 7 lists the measures that can be taken in an attempt to prevent *T. gondii* infection. Physicians are urged to make such written information available to their pregnant patients. Written materials are available through the March of Dimes and in a free, downloadable format at <http://www.toxoplasmosis.org/>.

Most important is to inform these women that all meat be prepared “well done” (not “pink” in the center). Meat should be heated throughout to at least 67°C (153°F). Freezing to at least –20°C (–4°F) for 24 h and thawing also kills *T. gondii* cysts [3, 52]. The process of curing meat does not necessarily result in a product free of parasite cysts [53].

**Secondary prevention (serological screening).** In addition to implementation of primary preventive measures in seronegative women, it is important to identify those women who acquire *T. gondii* infection during gestation, and if fetal infection is detected by prenatal testing, therapeutic options, including termination of pregnancy and antibiotic treatment of the fetus in utero, should be discussed with the patient. Women and their partners have the right to know whether their fetus is at risk for congenital toxoplasmosis or whether their fetus has already been infected. Congenital toxoplasmosis will continue to go largely undiagnosed in the United States in the absence of universal screening programs to detect acute *T. gondii* infection acquired during gestation and in the absence of effective and more widely distributed educational programs [1, 9, 54].

As an alternative, in the states of Massachusetts, New Hampshire, and Vermont, a secondary prevention program that performs *Toxoplasma* serological testing in all newborns has been underway for several years [55, 56]. Although postnatal screening of newborns identifies some subclinically infected infants, it has the potential to miss those infected late in the third

trimester but who have not yet formed antibodies, as well as infants infected early in gestation who are negative for IgM and IgA antibodies. Postnatal screening programs do not allow for measures that attempt to prevent congenital infection.

## Acknowledgments

**Potential conflicts of interest.** J.G.M. is director and J.S.R. is founder of and consultant for the Palo Alto Medical Foundation Toxoplasma Serology Laboratory.

## References

- Remington JS, McLeod R, Thulliez P, Desmonts G. Toxoplasmosis. In: Remington JS, Klein JO, Wilson CB, Baker C, eds. Infectious diseases of the fetus and newborn infant. 6th ed. Philadelphia: Elsevier Saunders, 2006:947–1091.
- Roberts T, Frenkel JK. Estimating income losses and other preventable costs caused by congenital toxoplasmosis in people in the United States. *J Am Vet Med Assoc* 1990;196:249–56.
- Dubey JP, Hill DE, Jones JL, et al. Prevalence of viable *Toxoplasma gondii* in beef, chicken, and pork from retail meat stores in the United States: risk assessment to consumers. *J Parasitol* 2005;91:1082–93.
- Bowie WR, King AS, Werker DH, et al. Outbreak of toxoplasmosis associated with municipal drinking water. *Lancet* 1997;350:173–7.
- Miller MA, Gardner IA, Kreuder C, et al. Coastal freshwater runoff is a risk factor for *Toxoplasma gondii* infection of southern sea otters (*Enhydra lutris nereis*). *Int J Parasitol* 2002;32:997–1006.
- Bahia-Oliveira LM, Jones JL, Azevedo-Silva J, Alves CC, Orefice F, Addiss DG. Highly endemic, waterborne toxoplasmosis in north Rio de Janeiro state, Brazil. *Emerg Infect Dis* 2003;9:55–62.
- de Moura L, Bahia-Oliveira LM, Wada MY, et al. Waterborne toxoplasmosis, Brazil, from field to gene. *Emerg Infect Dis* 2006;12:326–9.
- Lin YL, Liao YS, Liao LR, Chen FN, Kuo HM, He S. Seroprevalence and sources of *Toxoplasma* infection among indigenous and immigrant pregnant women in Taiwan. *Parasitol Res* 2008; published online Mar 8.
- Boyer KM, Holfels E, Roizen N, et al. Risk factors for *Toxoplasma gondii* infection in mothers of infants with congenital toxoplasmosis: implications for prenatal management and screening. *Am J Obstet Gynecol* 2005;192:564–71.

10. Garweg JG, Scherrer J, Wallon M, Kodjikian L, Peyron F. Reactivation of ocular toxoplasmosis during pregnancy. *BJOG* **2005**; 112:241–2.
11. Mitchell CD, Erlich SS, Mastrucci MT, Hutto SC, Parks WP, Scott GB. Congenital toxoplasmosis occurring in infants perinatally infected with human immunodeficiency virus 1. *Pediatr Infect Dis J* **1990**; 9:512–8.
12. Remington JS, McLeod R, Desmonts G. Toxoplasmosis. In: Remington JS, Klein JO, eds. *Infectious diseases of the fetus and newborn infant*. 4th ed. Philadelphia: W. B. Saunders, **1995**:140–267.
13. Wechsler B, Le Thi Huong D, Vignes B, Piette JC, Chomette G, Godeau P. Toxoplasmose et lupus: revue de la littérature a propos de 4 observations. *Ann Med Interne (Paris)* **1986**; 137:324–30.
14. Dunn D, Wallon M, Peyron F, Petersen E, Peckham C, Gilbert R. Mother-to-child transmission of toxoplasmosis: risk estimates for clinical counselling. *Lancet* **1999**; 353:1829–33.
15. Montoya JG. Laboratory diagnosis of *Toxoplasma gondii* infection and toxoplasmosis. *J Infect Dis* **2002**; 185(Suppl 1):S73–82.
16. Liesenfeld O, Press C, Montoya JG, et al. False-positive results in immunoglobulin M (IgM) toxoplasma antibody tests and importance of confirmatory testing: the Platelia Toxo IgM test. *J Clin Microbiol* **1997**; 35:174–8.
17. Public Health Service, Department of Health and Human Services; US Food and Drug Administration. FDA public health advisory: limitations of toxoplasma IgM commercial test kits. Rockville, MD: Department of Health and Human Services; US Food and Drug Administration, **1997**:3.
18. Wilson M, Remington JS, Clavet C, et al. Evaluation of six commercial kits for detection of human immunoglobulin M antibodies to *Toxoplasma gondii*. *J Clin Microbiol* **1997**; 35:3112–5.
19. Liesenfeld O, Montoya JG, Tathineni NJ, et al. Confirmatory serologic testing for acute toxoplasmosis and rate of induced abortions among women reported to have positive *Toxoplasma* immunoglobulin M antibody titers. *Am J Obstet Gynecol* **2001**; 184:140–5.
20. Lappalainen M, Hedman K. Serodiagnosis of toxoplasmosis: the impact of measurement of IgG avidity. *Ann Ist Super Sanita* **2004**; 40:81–8.
21. Roberts A, Hedman K, Luyasu V, et al. Multicenter evaluation of strategies for serodiagnosis of primary infection with *Toxoplasma gondii*. *Eur J Clin Microbiol Infect Dis* **2001**; 20:467–74.
22. Hedman K, Lappalainen M, Seppala I, Makela O. Recent primary *Toxoplasma* infection indicated by a low avidity of specific IgG. *J Infect Dis* **1989**; 159:736–9.
23. Lappalainen M, Koskela P, Koskiniemi M, et al. Toxoplasmosis acquired during pregnancy: improved serodiagnosis based on avidity of IgG. *J Infect Dis* **1993**; 167:691–97.
24. Pelloux H, Brun E, Vernet G, et al. Determination of anti-*Toxoplasma gondii* immunoglobulin G avidity: adaptation to the Vidas system (bioMérieux). *Diagn Microbiol Infect Dis* **1998**; 32:69–73.
25. Lappalainen M, Koskiniemi M, Hiilesmaa V, et al. Outcome of children after maternal primary *Toxoplasma* infection during pregnancy with emphasis on avidity of specific IgG. *Pediatr Infect Dis J* **1995**; 14: 354–61.
26. Romand S, Wallon M, Franck J, Thulliez P, Peyron F, Dumon H. Prenatal diagnosis using polymerase chain reaction on amniotic fluid for congenital toxoplasmosis. *Obstet Gynecol* **2001**; 97:296–300.
27. Montoya JG, Huffman HB, Remington JS. Evaluation of the immunoglobulin G avidity test for diagnosis of toxoplasmic lymphadenopathy. *J Clin Microbiol* **2004**; 42:4627–31.
28. Montoya JG, Liesenfeld O, Kinney S, Press C, Remington JS. VIDAS test for avidity of *Toxoplasma*-specific immunoglobulin G for confirmatory testing of pregnant women. *J Clin Microbiol* **2002**; 40:2504–8.
29. Grover CM, Thulliez P, Remington JS, Boothroyd JD. Rapid prenatal diagnosis of congenital *Toxoplasma* infection by using polymerase chain reaction and amniotic fluid. *J Clin Microbiol* **1990**; 28:2297–301.
30. Hohlfield P, Daffos F, Costa J-M, Thulliez P, Forestier F, Vidaud M. Prenatal diagnosis of congenital toxoplasmosis with polymerase-chain-reaction test on amniotic fluid. *N Engl J Med* **1994**; 331:695–9.
31. Romand S, Chosson M, Franck J, et al. Usefulness of quantitative polymerase chain reaction in amniotic fluid as early prognostic marker of fetal infection with *Toxoplasma gondii*. *Am J Obstet Gynecol* **2004**; 190:797–802.
32. Costa JM, Dardé ML, Assouline B, Vidaud M, Bretagne S. Microsatellite in the beta-tubulin gene of *Toxoplasma gondii* as a new genetic marker for use in direct screening of amniotic fluids. *J Clin Microbiol* **1997**; 35:2542–5.
33. Chabbert E, Lachaud L, Crobu L, Bastien P. Comparison of two widely used PCR primer systems for detection of *Toxoplasma* in amniotic fluid, blood, and tissues. *J Clin Microbiol* **2004**; 42:1719–22.
34. Bretagne S. Molecular diagnostics in clinical parasitology and mycology: limits of the current polymerase chain reaction (PCR) assays and interest of the real-time PCR assays. *Clin Microbiol Infect* **2003**; 9: 505–11.
35. Fricker-Hidalgo H, Brenier-Pinchart MP, Schaal JP, Equy V, Bost-Bru C, Pelloux H. Value of *Toxoplasma gondii* detection in one hundred thirty-three placentas for the diagnosis of congenital toxoplasmosis. *Pediatr Infect Dis J* **2007**; 26:845–6.
36. Berrebi A, Bardou M, Bessieres MH, et al. Outcome for children infected with congenital toxoplasmosis in the first trimester and with normal ultrasound findings: a study of 36 cases. *Eur J Obstet Gynecol Reprod Biol* **2007**; 135:53–7.
37. Conley FK, Jenkins KA, Remington JS. *Toxoplasma gondii* infection of the central nervous system: use of the peroxidase-antiperoxidase method to demonstrate *Toxoplasma* in formalin fixed, paraffin embedded tissue sections. *Hum Pathol* **1981**; 12:690–8.
38. Gilbert R, Gras L, European Multicentre Study on Congenital Toxoplasmosis. Effect of timing and type of treatment on the risk of mother to child transmission of *Toxoplasma gondii*. *BJOG* **2003**; 110:112–20.
39. Desmonts G, Couvreur J. Congenital toxoplasmosis: a prospective study of the offspring of 542 women who acquired toxoplasmosis during pregnancy. In: Thalhammer O, Pollak A, Baumgarten K, eds. *Perinatal medicine: proceedings of the 6th European Congress*, Vienna. Stuttgart, Germany: Georg Thieme Publishers, **1979**:51–60.
40. Forestier F. Les foetopathies infectieuses: prevention, diagnostic prenatal, attitude pratique. *Presse Med* **1991**; 20:1448–54.
41. Hohlfield P, Daffos F, Thulliez P, et al. Fetal toxoplasmosis: outcome of pregnancy and infant follow-up after in utero treatment. *J Pediatr* **1989**; 115:765–9.
42. Couvreur J, Desmonts G, Thulliez P. Prophylaxis of congenital toxoplasmosis: effects of spiramycin on placental infection. *J Antimicrob Chemother* **1988**; 22:193–200.
43. Thiebaut R, Leproust S, Chene G, Gilbert R. Effectiveness of prenatal treatment for congenital toxoplasmosis: a meta-analysis of individual patients' data. *Lancet* **2007**; 369:115–22.
44. Thulliez P. Commentary: efficacy of prenatal treatment for toxoplasmosis: a possibility that cannot be ruled out. *Int J Epidemiol* **2001**; 30:1315–6.
45. Kieffer F, Wallon M, Garcia P, Thulliez P, Peyron F, Franck J. Risk factors for retinochoroiditis during the first 2 years of life in infants with treated congenital toxoplasmosis. *Pediatr Infect Dis J* **2008**; 27: 27–32.
46. Foulon W, Villena I, Stray-Pedersen B, et al. Treatment of toxoplasmosis during pregnancy: a multicenter study of impact on fetal transmission and children's sequelae at age 1 year. *Am J Obstet Gynecol* **1999**; 180: 410–5.
47. Montoya JG, Remington JS. Toxoplasmic chorioretinitis in the setting of acute acquired toxoplasmosis. *Clin Infect Dis* **1996**; 23:277–82.
48. Foulon W, Naessens A, Lauwers S, De Meuter F, Amy JJ. Impact of primary prevention on the incidence of toxoplasmosis during pregnancy. *Obstet Gynecol* **1988**; 72:363–6.
49. Baril L, Ancelle T, Goulet V, Thulliez P, Tirard-Fleury V, Carme B. Risk factors for *Toxoplasma* infection in pregnancy: a case-control study in France. *Scand J Infect Dis* **1999**; 31:305–9.
50. Gollub EL, Leroy V, Gilbert R, Chene G, Wallon M. Effectiveness of health education on *Toxoplasma*-related knowledge, behaviour, and risk of seroconversion in pregnancy. *Eur J Obstet Gynecol Reprod Biol* **2008**; 136:137–45.

51. Wong S, Remington JS. Toxoplasmosis in pregnancy. *Clin Infect Dis* **1994**; 18:853–62.
52. Dubey JP, Lindsay DS, Speer CA. Structures of *Toxoplasma gondii* tachyzoites, bradyzoites, and sporozoites and biology and development of tissue cysts. *Clin Microbiol Rev* **1998**; 11:267–99.
53. Geurina NG, Hsu HW, Meissner HC, et al.; New England Regional Toxoplasma Working Group. Neonatal serologic screening and early treatment for congenital *Toxoplasma gondii* infection. *N Engl J Med* **1994**; 330:1858–63.
54. McCabe R, Remington JS. Toxoplasmosis: the time has come. *N Engl J Med* **1988**; 318:313–5.
55. Schmidt DR, Hogh B, Andersen O, Fuchs J, Fledelius H, Petersen E. The national neonatal screening programme for congenital toxoplasmosis in Denmark: results from the initial four years, 1999–2002. *Arch Dis Child* **2006**; 91:661–5.
56. Guerina N, Hsu H-W, Meissner H, et al. Neonatal serologic screening and early treatment for congenital *Toxoplasma gondii* infection. *N Engl J Med* **1994**; 330:1858–63.